

Polymyxin B-immobilized Fiber Column Hemoperfusion Treatment for Drug-Induced Severe Respiratory Failure: Report of Three Cases

Toshiki Yokoyama, Kenji Tsushima, Hiroshi Yamamoto, Michiko Ito,
Toshihiko Agatsuma, Tomonobu Kozumi and Keishi Kubo

Abstract

The effects of direct hemoperfusion with polymyxin B-immobilized fiber (PMX-DHP) treatment for acute exacerbation of interstitial pneumonia have been reported. Here, we report 3 severe cases of drug-induced interstitial lung disease (DI-ILD) that were treated with PMX-DHP. Two DI-ILD cases were caused by methotrexate, and the third case was caused by the herbal medicine sanmotsu-ogon-to. The arterial oxygen tension/inspiratory oxygen fraction ratio improved during PMX-DHP treatment in all 3 patients. Finally, 2 patients survived and 1 died. The study findings indicate that PMX-DHP treatment is a viable option for the management of acute respiratory failure in patients with DI-ILD.

Key words: interstitial lung disease, polymyxin B-immobilized fiber column treatment, drug-induced lung disease, Krebs von den Lungen-6 (KL-6)

(Inter Med 49: 59-64, 2010)

(DOI: 10.2169/internalmedicine.49.2213)

Introduction

Recently, it was reported that some new drugs, in particular, leflunomide, which belongs to a new class of disease-modifying antirheumatic drugs (1), and gefitinib, a new molecular agent targeting lung cancer (2), can induce severe interstitial lung disease. There are also some reports of severe respiratory failure or acute respiratory distress syndrome (ARDS) resulting from the use of other drugs, such as methotrexate (MTX) (3), and certain herbal medicines (4, 5).

In general, discontinuance of the original drug is standard therapy for drug-induced cases of interstitial lung disease (DI-ILD) (3). Some studies have reported that corticosteroid therapy is effective for DI-ILD; (6) however, steroid therapy alone is inadequate for the treatment of certain conditions. There is no advanced treatment strategy established for severe DI-ILD in cases wherein corticosteroid therapy is ineffective. In the case of idiopathic interstitial pneumonia, cyclophosphamide (7) and cyclosporin (8) can be administered

as immunosuppressive therapies. Therefore, it might be appropriate to consider using these immunosuppressive therapies for DI-ILD. However, to date, the use of immunosuppressive agents as therapeutic drugs for the treatment of DI-ILD has not been reported.

Direct hemoperfusion with polymyxin B-immobilized fiber (PMX-DHP) treatment is reported to be effective for septic shock as PMX-DHP adsorbs the endotoxin in patients with sepsis (9). Recent reports suggest that PMX-DHP treatment improves oxygenation in patients with acute lung injury (ALI)/ARDS (10). In this case report, we investigated the effectiveness of PMX-DHP treatment in DI-ILD patients with severe acute respiratory failure.

Case Report

General management of DI-ILD

First, we discontinued the original drug that caused DI-ILD. As a standard therapy, the patient was treated with high-dose corticosteroid therapy (1 g/d of methylprednisolone).

lone for 3 d). This therapy was repeated 3-4 times until the patient was withdrawn from mechanical ventilation, at which time the dose of corticosteroid was reduced to 1 mg·kg⁻¹·d⁻¹ of prednisolone. To rule out congestive heart failure, ultrasound cardiography was performed. Cultures of sputum, blood, and urine were performed to detect bacteria, fungus, and mycobacterium and thereby exclude infectious diseases, especially, sepsis.

Inclusion criteria of PMX-DHP

We defined the criterion for the introduction of PMX-

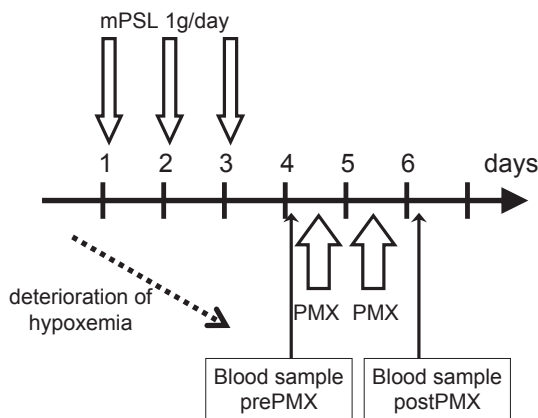


Figure 1. PMX-DHP treatment strategy. Blood sample: Arterial oxygen tension (PaO₂), white blood cell (WBC), neutrophil, C-reactive protein (CRP), lactate dehydrogenase (LDH), Krebs von den Lungen-6 (KL-6).

DHP as a decrease in the arterial oxygen concentration (PaO₂)/inspiratory oxygen fraction (FiO₂) (P/F) ratio by more than 10 Torr from the baseline, despite the administration of corticosteroid therapy.

Direct hemoperfusion was carried out at a flow rate of 80-100 mL/min for 2 hour. PMX-DHP treatment was performed twice at an interval of approximately 24 hour. Nafamostat mesilate (Torii Pharma, Tokyo, Japan) was used as an anticoagulant in the case of all patients.

The length of PMX-DHP treatment varied in this study, depending on the column condition. The treatment was carried out for at least 2 hour, and if possible, the treatment time was extended until the pressure in the column was elevated. If the P/F ratio improved by more than 10 during PMX-DHP treatment on the first day, we resumed the treatment on the following day. Circulating Krebs von den Lungen-6 (KL-6) and lactate dehydrogenase (LDH) levels were measured to evaluate the effectiveness of PMX-DHP treatment. The circulating white blood cell (WBC) and neutrophil counts as well as the C-reactive protein (CRP), KL-6 and LDH levels were determined just before PMX-DHP treatment and the morning after administration of the second PMX-DHP treatment (Fig. 1).

The protocol for PMX-DHP treatment was approved by the Human Ethics Review Committee of Shinshu University School of Medicine. The patients or their families provided written informed consent before PMX-DHP treatment.

The characteristics and outcomes of PMX-DHP in the patients were shown in Table 1.

Table 1. Characteristics and Outcome of PMX-DHP Treatment in the Patients

	Case 1	Case 2	Case 3
Age	77	61	65
Sex	female	male	male
Original drug	Methotrexate	Methotrexate	Herbal medicine : Sanmotsu-ogon-to
Outcome	died	survived	survived
PaO ₂ /FiO ₂ before 1 st PMX-DHP	245.0	96.0	78.6
PaO ₂ /FiO ₂ after 2 nd PMX-DHP	351.0	138.4	140.5
Pre-treatment before 1 st PMX-DHP			
Corticosteroid pulse therapy	4 times	2 times	1 time
Cyclophosphamide	none	1 time	1 time

PMX-DHP: Direct hemoperfusion with polymyxin B-immobilized fiber

PaO₂/FiO₂: Arterial oxygen tension/inspiratory oxygen fraction

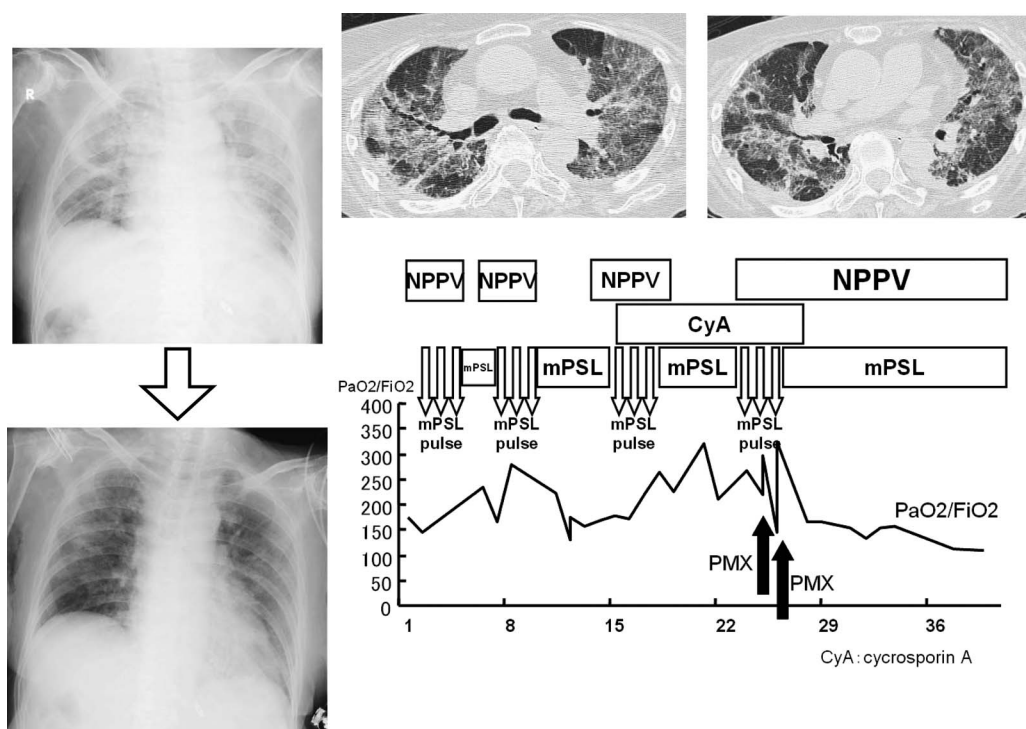


Figure 2. Chest radiographs, CT scans, and clinical course of case 1.

Case 1

A 77-year-old woman was admitted because of fever and dyspnea. She had suffered from rheumatoid arthritis (RA) for 7 years and was treated with MTX. The radiological findings revealed that she had bilateral ground-glass opacity. Mechanical ventilation with noninvasive ventilation was initiated because of severe hypoxemia. Bronchofiberscopy (BFS) and bronchoalveolar lavage (BAL) were conducted to exclude infectious disease, and corticosteroid therapy was initiated. Finally, because the drug lymphocyte stimulating test (DLST) was positive for MTX, she was diagnosed with DI-ILD caused by MTX.

PMX-DHP treatment was initiated during the fourth high-dose corticosteroid therapy because the P/F ratio had decreased to 245 from 287 despite steroid therapy. The P/F ratio improved from 245 to 351 during the PMX-DHP treatment. The circulating WBC count, neutrophil numbers, and CRP levels improved, but the circulating KL-6 and LDH levels increased despite PMX-DHP treatment. After PMX-DHP treatment, the patient was treated with cyclosporin A, which induced hepatocellular damage. She died due to severe liver dysfunction on day 23 after the start of the PMX-DHP treatment (Fig. 2).

Case 2

A 61-year-old man was admitted because of a cough, dyspnea, and sputum. He had suffered from rheumatoid arthritis (RA) for 20 years and was treated with MTX. Chest CT findings showed diffuse ground-glass opacity and regions of consolidation. Because of severe hypoxemia, he required mechanical ventilation and endotracheal intubation.

We could not perform BFS and BAL. Antibiotic agents were used against bacterial pneumonia, but this treatment was ineffective. He was clinically diagnosed with DI-ILD due to MTX as the DLST for this drug was positive, and corticosteroid therapy was initiated.

PMX-DHP treatment was initiated after the second high-dose corticosteroid therapy. The patient had received cyclophosphamide (CPA) pulse therapy (500 mg/m²) 2 d prior to the PMX-DHP treatment, but the CPA pulse therapy was not effective. The P/F ratio worsened from 160.3 to 96 on the day before the initiation of PMX-DHP treatment. The WBC count, neutrophil numbers, and CRP levels improved during PMX-DHP treatment. The serum LDH level improved and serum KL-6 level remained the same. The P/F ratio improved from 96 to 138.4 during PMX-DHP treatment. Five days after the end of PMX-DHP treatment, the P/F ratio worsened to 112.5, and the patient was intubated. Despite intubation, the P/F ratio continued to worsen to 94.4. During the third PMX-DHP treatment, the P/F ratio improved from 94.4 to 123.7. The patient survived but was dependent on mechanical ventilation because of pulmonary fibrosis induced by the lung injury (Fig. 3).

Case 3

A 65-year-old man was diagnosed with acute pneumonia and treated with antibiotic therapy in another hospital. However, it did not improve his condition, and high-dose corticosteroid therapy was initiated. Then, he was admitted to our hospital due to severe hypoxemia. Examination of his past history revealed that he had used herbal medicine, namely, sanmotsu-ogon-to for leg pain 1 month before admission in the previous hospital. He was clinically diag-

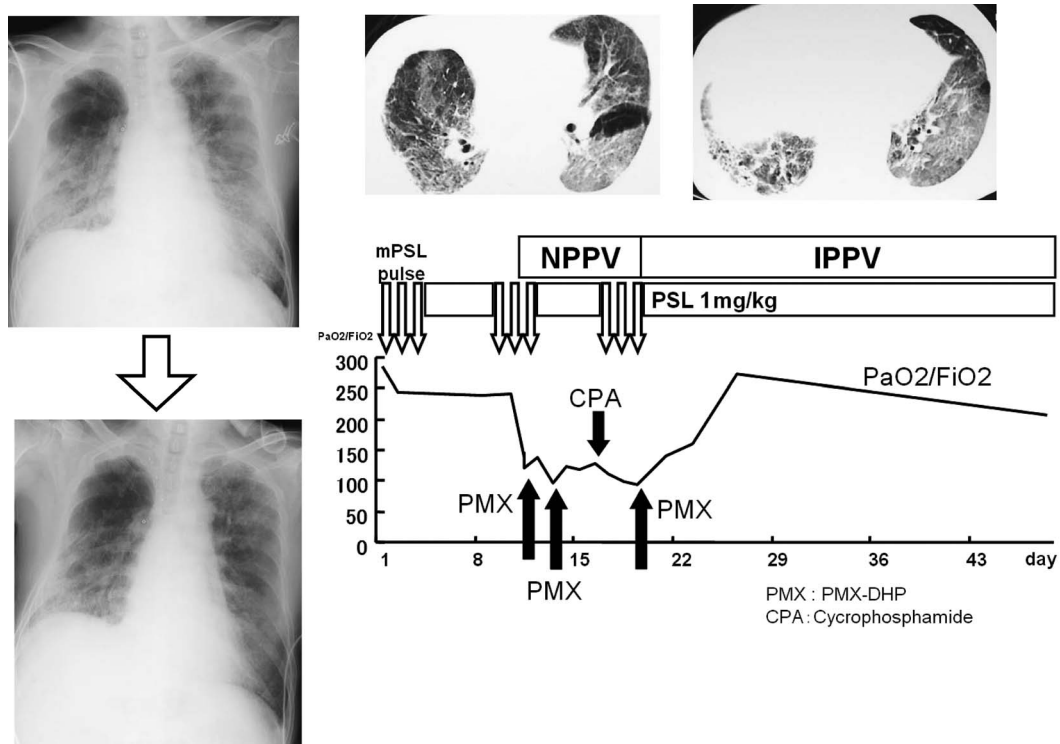


Figure 3. Chest radiographs, CT scans, and clinical course of case 2.

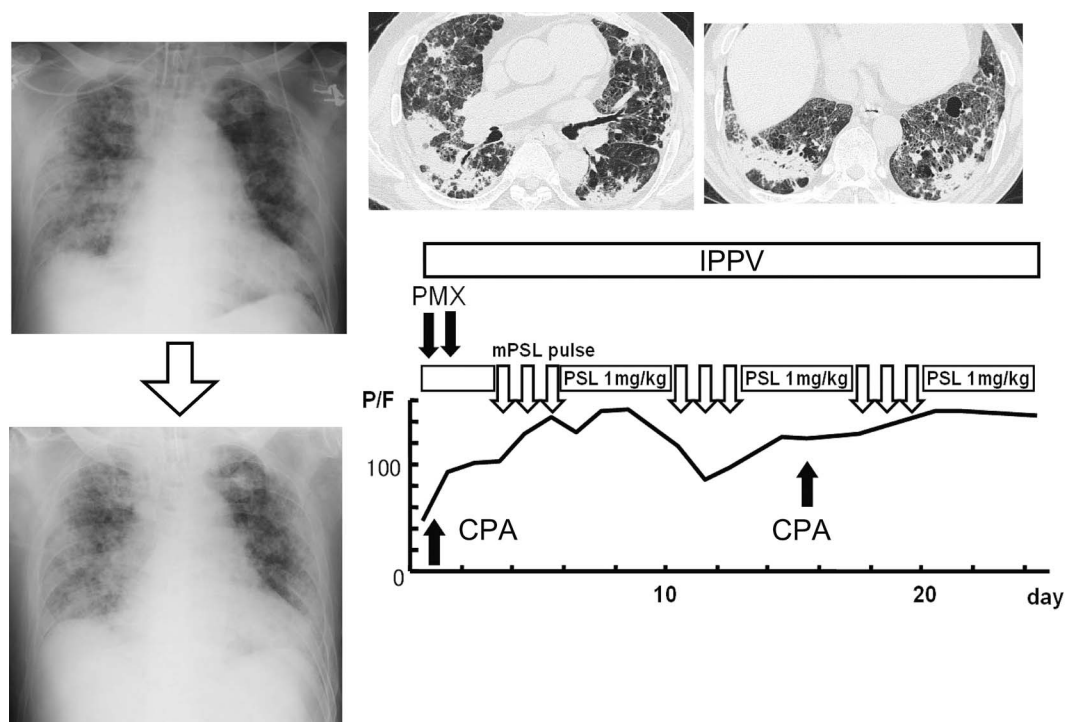


Figure 4. Chest radiographs, CT scans, and clinical course of case 3.

nosed with DI-ILD caused by this herbal medicine, but the DLST could not be conducted because corticosteroid therapy had already been administered in the previous hospital. He required mechanical ventilation and endotracheal intubation due to severe hypoxemia. We could not perform BAL.

The P/F ratio had already decreased to 78.6 during the first high-dose corticosteroid therapy in the other hospital. We could not confirm the P/F ratio before the corticosteroid

therapy in the previous hospital. However, since the FiO₂ level increased and SpO₂ level had decreased during corticosteroid therapy, it was suggested that the P/F ratio had decreased. Because of the ineffectiveness of high-dose corticosteroid therapy, PMX-DHP treatment was introduced, and subsequently, his hypoxemia improved. The WBC count; neutrophil numbers; and CRP, serum LDH, and KL-6 levels improved during the 2 d of PMX-DHP treatment. The pa-

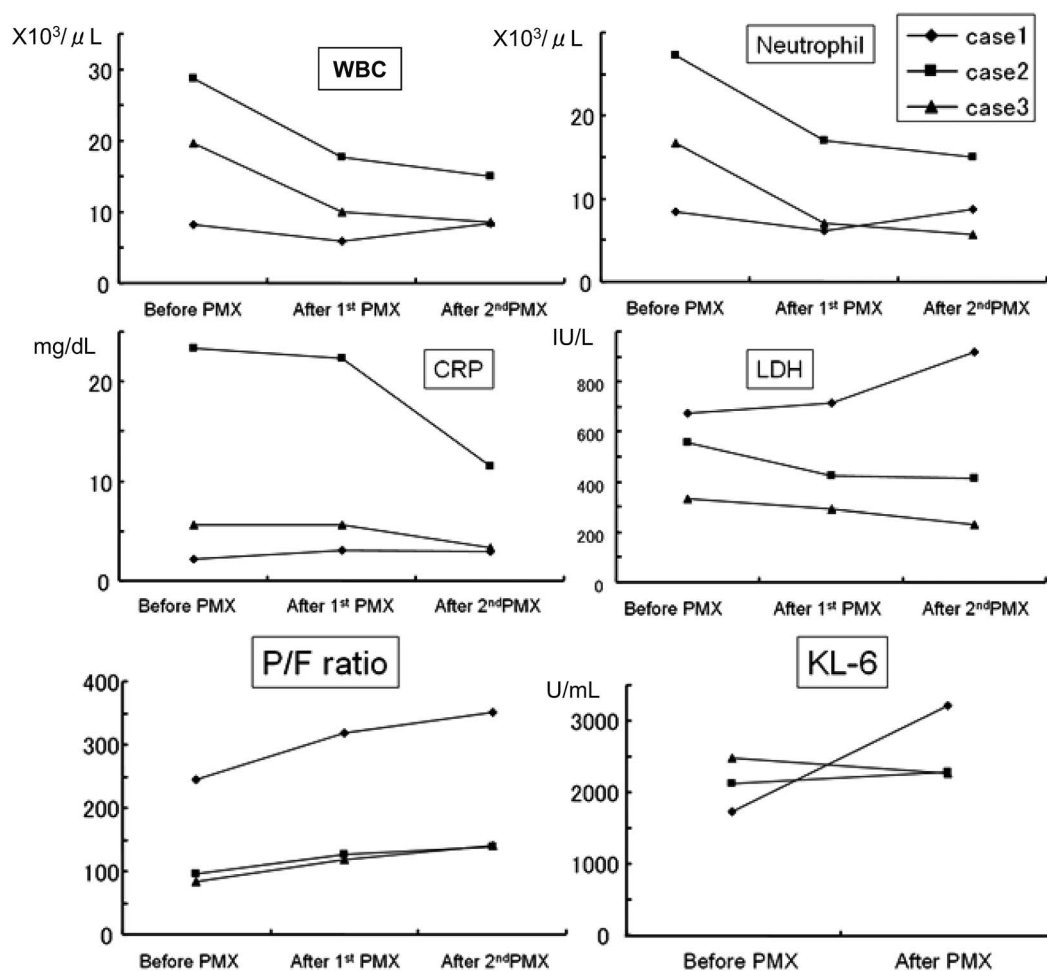


Figure 5. Change in laboratory data after direct hemoperfusion with polymyxin B-immobilized fiber (PMX-DHP).

WBC: white blood cell, CRP: C-reactive protein, LDH: lactate dehydrogenase, KL-6: Krebs von den Lungen-6

tient was treated with CPA pulse therapy biweekly. On day 66 after admission, he was withdrawn from mechanical ventilation and he survived (Fig. 4).

Discussion

We demonstrated the potential beneficial effects of PMX-DHP treatment for DI-ILD patients. PMX-DHP treatment has been used in Japan since 1994 as a treatment for sepsis or septic shock. The PMX column was developed for the adsorption of endotoxins in blood. Originally, PMX-DHP treatment was shown to be effective against sepsis caused by gram-negative rods, and it improved the hemodynamic status. A multicenter clinical study that included many patients with ARDS revealed that the treatment of septic shock with PMX-DHP was associated with a reduction in the concentration of endotoxins, and there was a decrease in the mortality rate (9). Our group reported that PMX-DHP treatment improved both the hemodynamic instability and oxygenation during endotoxemia in anesthetized sheep (11). We proposed that PMX-DHP treatment would simultaneously improve oxygenation because the production of inflamma-

tory cytokines was suppressed (10, 12).

The effects of PMX-DHP treatment on acute respiratory failure during interstitial lung disease have not been established. Recently, Seo et al reported that PMX-DHP treatment is effective against acute exacerbation of idiopathic pulmonary fibrosis (IPF) (13). In any case, the pathological finding of acute exacerbation of IPF is diffuse alveolar damage (DAD). However, the mechanism underlying the effect of PMX-DHP treatment in these situations is unclear. In previous reports, PMX-DHP treatment was found to improve the inflammation due to DAD via a decrease in the level of activated neutrophils. Kushi et al (12) reported that the improved oxygenation during PMX-DHP treatment was related to the decline in circulating neutrophil elastase and IL-8 in patients with septic ALI/ARDS. They concluded that PMX-DHP treatment could reduce the levels of inflammatory cytokines and suppress the activation of neutrophils. Activated neutrophils play a key role in DAD (14). Alveolar macrophages secrete cytokines and chemokines, which act locally to stimulate chemotaxis and activate neutrophils. Neutrophils are shown to adhere to the injured capillary endothelium and marginate through the interstitium into the air space,

which is filled with protein-rich edema fluid. Activated neutrophils release oxidants, elastase, and other proinflammatory molecules. Thus, they induce epithelial cell and extracellular matrix injury with the formation of protein-rich hyaline membranes (14). It is reported that some of the severe cases with DI-ILD showed DAD in pathological findings (2, 3). Activated neutrophils may play an important role in the development of DI-ILD in severe cases in which corticosteroid therapy is ineffective. In this study, the level of circulating neutrophils was reduced after PMX-DHP treatment. However, it is suggested that lymphocytes generally play a key role in the development of DI-ILD. It is still unclear whether or not the function of lymphocytes clarify the mechanism to develop to DAD. We only suggested this hypothesis based on the many case reports (2, 3). Unfortunately, we could not confirm the adsorption of inflammatory cytokines on the column.

Although the mechanism underlying the effect of PMX-DHP treatment has not yet been elucidated, treatment with PMX-DHP was found to improve the oxygenation in DI-ILD patients. We have compiled many case reports in which PMX-DHP was used as a management strategy for DAD. Previous reports have described that some patients with severe DI-ILD showed DAD findings (3). In the present study, 2 patients survived despite severe respiratory failure. In fact, oxygenation improved after PMX-DHP treatment in cases wherein corticosteroid therapies were not effective. However, the serum KL-6 and LDH levels did not improve (Fig. 5). We could not determine whether PMX-DHP treatment effectively suppressed pulmonary fibrosis. We assumed that PMX-DHP treatment might improve oxygenation alone. In these 3 patients, hypoxemia improved only during the PMX-DHP treatment but deteriorated several days after the

completion of PMX-DHP treatment. Thus, the good oxygenation conditions could not be maintained after PMX-DHP treatment was completed.

It is very difficult to explain the mechanism by which PMX-DHP treatment increases the P/F ratio. We suggest that PMX-DHP treatment temporarily affects oxygenation. In these 3 cases, the combination with sepsis was denied. Sepsis was not related to the mechanism of the effectiveness using PMX-DHP. We suggest that the improvement of intrapulmonary shunting with microcirculatory dysfunction resulted in better hemodynamic instability in the lung because of the adsorption of some unknown chemical mediator (11). The improvement in oxygenation was only temporary. It is not clear whether PMX-DHP treatment will improve the survival rate in the case of DI-ILD patients. DI-ILD is a lung injury caused by drugs. If the original drug is discontinued, there is a chance that the lung injury will improve. In the case of DI-ILD, temporary improvement in oxygenation may provide beneficial effects for patients. Actually, the 2 surviving cases in our study had survived for over one year after discharge. Further studies are required to clarify this hypothesis.

Therefore, we think that PMX-DHP treatment is beneficial for DI-ILD patients as it improves oxygenation. However, the efficacy of PMX-DHP treatment for DI-ILD could not be validated in this study due to 2 limitations, namely, the small number of patients and the absence of a control group.

Abbreviations: PaO₂/FiO₂: Arterial oxygen tension/inspiratory oxygen fraction, NPPV: Noninvasive positive pressure ventilation, IPPV: Invasive positive pressure ventilation, mPSL: Methylprednisolone, PSL: Prednisolone, CyA: Cyclosporin A

References

- Kamata Y, Nara H, Kamimura T, et al. Rheumatoid arthritis complicated with acute interstitial pneumonia induced by leflunomide as an adverse reaction. *Intern Med* **43**: 1201-1204, 2004.
- Inoue A, Saijo Y, Maemondo M, et al. Severe acute interstitial pneumonia and gefitinib. *Lancet* **361**: 137-139, 2003.
- Imokawa S, Colby TV, Leslie KO, Helters RA. Methotrexate pneumonitis: review of the literature and histopathological findings in nine patients. *Eur Respir J* **15**: 373-381, 2000.
- Shiota Y, Wilson JG, Mashiba H. Adult respiratory distress syndrome induced by a Chinese medicine, Kamisyoyo-San. *Intern Med* **35**: 494-496, 1996.
- Sakamoto O, Ichikado K, Kohroggi H, Suga M. First clinical and CT characteristics of Chinese medicine-induced acute respiratory distress syndrome. *Respirology* **8**: 344-350, 2003.
- Kataoka K, Taniguchi H, Hasegawa Y, et al. Interstitial lung disease associated with gefitinib. *Respir Med* **100**: 698-704, 2006.
- Kondoh Y, Taniguchi H, Yokoi T, et al. Cyclophosphamide and low-dose prednisolone in idiopathic pulmonary fibrosis and fibrosing nonspecific interstitial pneumonia. *Eur Respir J* **25**: 528-533, 2005.
- Homma S, Sakamoto S, Kawabata M, et al. Cyclosporin treatment in steroid-resistant and acutely exacerbated interstitial pneumonia. *Intern Med* **44**: 1144-1150, 2005.
- Kodama M, Tani T, Hanasawa H; The PMX Clinical Study Group. Treatment of sepsis by plasma endotoxin removal: hemoperfusion using a polymyxin-B immobilized column. *J Endotoxin Res* **4**: 293, 1997.
- Tsushima K, Kubo K, Yoshikawa S, et al. Effects of PMX-DHP treatment for patients with directly induced acute respiratory distress syndrome. *Ther Apher Dial* **11**: 138-145, 2007.
- Yamamoto H, Koizumi T, Kaneki T, Fujimoto K, Kubo K, Honda T. Direct hemoperfusion with polymyxin B immobilized fiber improves shock and hypoxemia during endotoxemia in anesthetized sheep. *J Endotoxin Res* **8**: 419-426, 2002.
- Kushi H, Miki T, Okamoto K, Nakahara J, Saito T, Tanjoh K. Early hemoperfusion with an immobilized polymyxin B fiber column eliminates humoral mediators and improves pulmonary oxygenation. *Crit Care* **9**: 653-661, 2005.
- Seo Y, Abe S, Kurahara M, et al. Beneficial effect of polymyxin B-immobilized fiber column (PMX) hemoperfusion treatment on acute exacerbation of idiopathic pulmonary fibrosis. *Intern Med* **45**: 1033-1038, 2006.
- Ware LB, Matthay MA. The acute respiratory distress syndrome. *N Engl J Med* **342**: 1334-1349, 2000.